

Intracystic Papillary Carcinoma of The Breast: A Case Report

Memenin İntrakistik Papiller Karsinomu: Olgu Sunumu
Genel Cerrahi

Başvuru: 19.03.2014
Kabul: 28.04.2014
Yayın: 13.05.2014

Köksal Bilgen¹, Şahin Kahramanca², Murat Karakahya¹, Hasan Öztürk³, Nurcan Salman⁴, Hakan Güzel⁵,
Gündüz Tunç⁶

¹ Ordu Üniversitesi Eğitim ve Araştırma Hastanesi

² Kars Devlet Hastanesi

³ Ordu İli Kamu Hastaneleri Birliği Genel Sekreteri

⁴ Ordu Devlet Hastanesi

⁵ Işkapı Yıldırım Beyazıt Eğitim ve Araştırma Hastanesi

⁶ Özel Çankaya Hastanesi

Özet

Altmış üç yaşında kadın hasta, sol memede ağrısız palpabil kitle nedeniyle genel cerrahi polikliniğine başvurdu. Mammografik incelemede kalifikasyonu olmayan oval bir kitle tespit edildi. Ultrasonografik incelemede 12x5 mm'lik solid komponenti olan 27x25 mm'lik kistik bir lezyon rapor edildi. Kistin solid komponentinden yapılan ince iğne aspirasyon biyopsisi non-diagnostik olarak geldi. Eksizyonel biyopsi yapıldı ve histopatolojik incelemede kitlenin cerrahi sınırlarında duktal karsinoma in-situ odakları olan intrakistik papiller karsinom olarak rapor edildi. Hastaya cerrahi sınırları negatif olan daha geniş bir re-eksizyon (lumpektomi) yapıldı. Herhangi bir komplikasyon gelişmeyen hasta posoperatif 2. günde taburcu edildi. Kemoterapi veya adjuvan radyoterapi planlanmayan hastaya sadece Tamoxifen sitrat 20 mg/gün reçete edildi. Aksiller lenf nodu diseksiyonu olmaksızın yapılan parsiyel mastektomi non-invaziv intrakistik papiller karsinom için standart tedavidir. Ancak halen adjuvan radyoterapi ve hormonoterapi üzerinde konsensus bulunmamaktadır. En son çalışmalar intrakistik papiller karsinomun, eşlik eden patolojiye göre tedavisini önermektedir.

Anahtar kelimeler: İntrakistik papiller karsinom, Duktal karsinoma in situ Postmenopozal kadın

Abstract

A 63-years old postmenopausal woman admitted to general surgery department with a painless palpable sub-areolar mass on her left breast. Mammography (MMG) demonstrated an oval mass without calcification. Ultrasound examination revealed a 27x25 millimeters (mm) cystic lesion in dimensions including a 12x5 mm solid component with regular margins. Fine needle aspiration biopsy (FNAB) of the solid component of the cyst was reported as non-diagnostic material. Excisional biopsy was performed, but histopathological examination was reported as intracystic papillary carcinoma with foci of DCIS on the surgical margins of the mass. A wide re-excision was planned as lumpectomy performed with achieving tumor free margins. Patient was discharged postoperative second day of the surgery without any complication. Neither adjuvant radiation nor chemotherapy was planned. She was administered Tamoxifen Citrate (20mg/day) postoperatively. Partial mastectomy without axillary lymph node dissection is the standard treatment for patients with non-invasive IPC but there is still no concensus on adjuvant radiation and endocrine therapy. Recent studies suggest that IPC should be managed according to the associated lesion.

Keywords: Intracystic papillary carcinoma, Duktal carcinoma in situ Postmenopausal woman

Introduction

Intracystic papillary carcinoma (IPC) is a rare, low-grade carcinoma of the breast with predilection for elderly women especially in the postmenopausal period and has an excellent prognosis for patients. IPC is a variant of

papillary carcinoma and accounts for 0,5% to 1% of breast cancer ¹. IPC had been divided into three subtypes: pure IPC, IPC with ductal carcinoma in situ (DCIS), and IPC with invasion. The associated lesion is closely related with the prognosis ².

Here, we report a postmenopausal woman who was diagnosed with IPC plus DCIS and highlight the need of a prudent approach to the cystic breast lesions in the postmenopausal period.

Case Report

A 63-years old postmenopausal woman admitted to general surgery department with a painless palpable mass on her breast. There was no abnormal nipple discharge. Family and past medical history of the patient were insignificant for breast cancer.

Physical examination revealed a palpable mass in the retroareolar area with no palpable axillary lymphadenopathy. Mammography (MMG) demonstrated an oval mass without calcification (Figure 1).

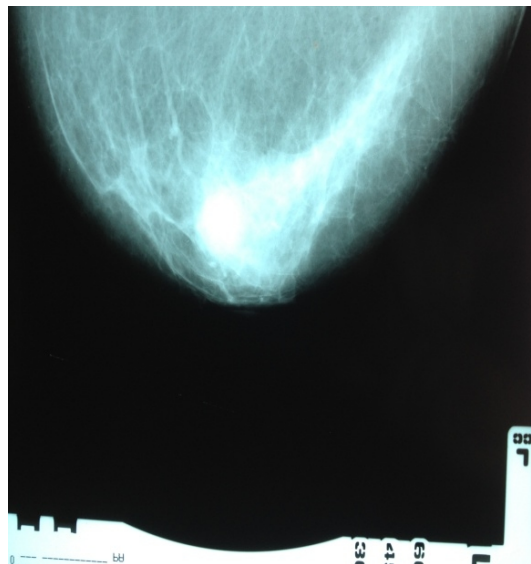


Figure 1

Mammography (MMG) demonstrated an oval subareolar mass without calcification.

There was a 27x25 mm well-defined cystic lesion in diameter including a 12x5 mm solid component with regular margins and posterior acoustic shadowing on ultrasound examination (Figure 2). Fine needle aspiration biopsy of the solid component of the cyst reported as non-diagnostic material.

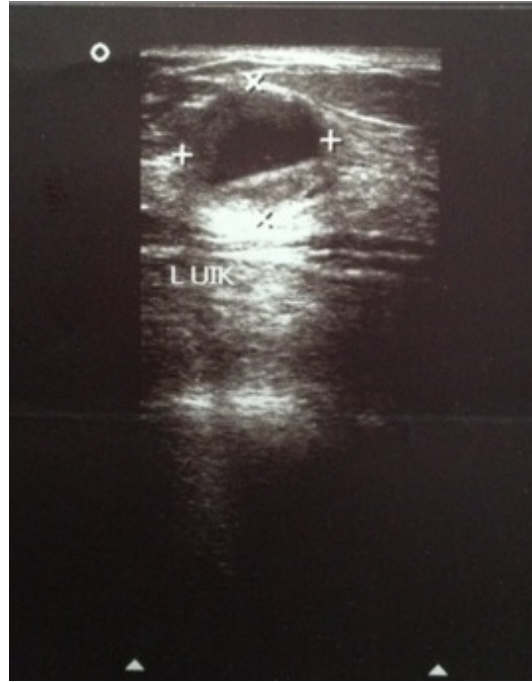


Figure 2

Ultrasound (USG) examination demonstrated a 27x25 mm well-defined cystic lesion in diameter including a 12x5 mm solid component with regular margins and posterior acoustic shadowing.

Total excisional biopsy was performed. Post-operative histological examination of paraffin blocks revealed an intracystic papillary carcinoma with the foci of DCIS on the surgical margins (Figure 3). A wide re-excision was planned as lumpectomy performed with achieving tumor free margins.

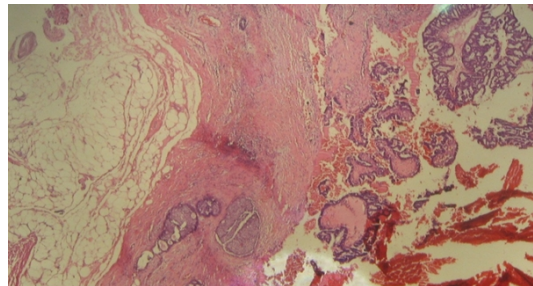


Figure 3

Histopathological examination demonstrated papillary structures in the fibrovascular stroma and foci of DCIS in the surrounding tissue, H&E 100X

Immunohistochemical study showed complete negativity of P63 and myo-epithelial cell staining of the tumor with smooth muscle actin was negative. Estrogen and progesterone receptor profiles of the patient were both positive. There was no over-expression of C-erb-B2 oncoprotein. Patient was discharged postoperative second day of the surgery without any complication. According to medical oncology department consultation; neither adjuvant radiation nor chemotherapy therapy was administered. She was administered Tamoxifen Citrate (20mg/day) postoperatively.

Discussion

IPC is a variant of papillary carcinoma and accounts for 0,5% to 1% of breast cancer ¹. There is an excellent prognosis for patients with IPC. A review of 917 patients with IPC showed greater than 95% survival rate at ten years ³. However it has been shown to present histologically with invasion of basement membrane and even metastasis ⁴. Because of its rarity and the wide range of histopathological behavior there is still no consensus on management of IPC.

Solorzano et al stated that the diagnosis of IPC often required excisional biopsy. They showed that FNA was inconclusive or nondiagnostic 41% of cases and core needle biopsy (CNB) can not rule out invasion in 30% of cases in their study ⁵. The diagnosis of the present case was achieved with performing total excisional biopsy, because the fine needle aspiration biopsy (FNAB) of solid component of the cyst was reported as non-diagnostic material.

Leal et al stated that IPC is usually a low-grade carcinoma presenting with low or intermediate nuclear grade, no necrosis, high estrogen receptor positivity, and negativity for c-erbB-2. They reported that associated DCIS can be found in as many as 46% of cases, and invasive carcinoma can be found in as many as 38% ⁶. The associated lesion of the present IPC case was DCIS. Histopathological examination of the case demonstrated papillary structures in the fibrovascular stroma and foci of DCIS in the surrounding tissue. Immunohistochemical study showed complete negativity of P63 and myo-epithelial cell staining of the tumor with smooth muscle actin was negative. Estrogen and progesterone receptor profiles of the patient were both positive. There was no over-expression of C-erb-B2 oncoprotein.

In the cases of IPC alone, IPC with DCIS, or IPC with invasion, complete local excision of the tumour with clear margins is the recommended surgical treatment ⁷. Since IPC rarely involves lymph nodes, partial mastectomy without axillary lymph node dissection is the standard treatment for patients with non-invasive IPC ^{5,8}. But the association with invasive carcinoma and the difficulty in evaluating the focus of invasive lesion may indicate sentinel axillary lymph node biopsy for IPC ^{5,9,10}. Lymph node involvement in pure IPC or IPC plus DCIS has not been reported but Wasserberg et al reported that 7% of patients with IPC plus DCIS with microinvasion had axillary lymph node involvement and 2% of those had distant metastasis ¹¹. In the present case there was no microinvasion focus histopathologically so we planned the surgery as partial mastectomy procedure without SLNB for this patient.

There is still no consensus on adjuvant radiation and endocrine therapy. A retrospective study of Fayanju et al including 45 woman with pure IPC indicates that only patients with pure IPC who are of young age (<50 years) should be considered for adjuvant radiation therapy. There has been no clear indication for adjuvant endocrine therapy either ^{7,12}. But this type of tumor is strongly estrogen receptor positive and hormonal therapy should be considered for its management ⁴. In the present case, neither adjuvant radiation nor chemotherapy was planned. She was administered only Tamoxifen Citrate (20mg/day) postoperatively.

Cystic lesions of the breast in postmenopausal period deserve a prudent approach due to presence of a potential malignancy. IPC has an excellent prognosis if the management is planned according to the associated lesion. Further studies in larger series of IPC cases with long follow-up periods are needed to establish a consensus in the management of IPC.

References

1. Collins LC, et al. Intracystic papillary carcinomas of the breast: a reevaluation using a panel of myoepithelial cell markers. *Am J Surg Pathol.* 2006; 30; 1002–7.

2. Carter D, Orr SL, Merino MJ. Intracystic papillary carcinoma of the breast. After mastectomy, radiotherapy or excisional biopsy alone. *Cancer*. 1983;52:14–9.
3. Grabowski J, et al. Intracystic papillary carcinoma: a review of 917 cases. *Cancer*. 2008 ;113(5):916-20. doi: 10.1002/cncr.23723.
4. Wynveen CA, et al. Intracystic papillary carcinoma of the breast: An in situ or invasive tumor? Results of immunohistochemical analysis and clinical follow-up. *Am J Surg Pathol* 2011;35(1):1–14.
5. Solorzano CC, et al. Treatment and outcome of patients with intracystic papillary carcinoma of the breast. *Am J Surg*. 2002; 184 (4):364–8.
6. Leal C, et al. Intracystic (encysted) papillary carcinoma of the breast: a clinical, pathological, and immunohistochemical study. *Hum Pathol*. 1998;29:1097–104.
7. Harris KP, et al. Treatment and outcome of intracystic papillary carcinoma of the breast. *Br J Surg*. 1999;86: 1274-5.
8. Esposito NN, Dabbs DJ, Bhargava R. Are encapsulated papillary carcinomas of the breast in situ or invasive? A basement membrane study of 27 cases. *Am J Clin Pathol*. 2009;131:228–42.
9. Okita R, et al. Synchronous liver metastases of intracystic papillary carcinoma with invasion of the breast. *Breast Cancer*. 2005;12:327-30.
10. Mulligan AM, O'Malley FP. Metastatic potential of encapsulated (intracystic) papillary carcinoma of the breast: a report of 2 cases with axillary lymph node micrometastases. *Int J Surg Pathol*. 2007;15(2):143–7.
11. Wasserberg N, et al. Risk factors for lymph node metastases in breast ductal carcinoma in situ with minimal invasive component. *Arch Surg*. 2002;137(11):1249-52.
12. Fayanju OM, et al. Therapeutic management of intracystic papillary carcinoma of the breast: the roles of radiation and endocrine therapy. *Am J Surg*. 2007;194:497-500.

Information Presentation

12. Ulusal Meme Hastalıkları Kongresi 24-27 Ekim 2013, Antalya