

Multiple Skull and Intracranial Metastasis of Follicular Thyroid Carcinoma: Case Report

Multiple Skull and Intracranial Metastasis of Follicular Thyroid Carcinoma: Case Report
Beyin ve Sinir Cerrahisi

Başvuru: 07.02.2013
Kabul: 04.03.2013
Yayın: 08.03.2013

Ali Ender Ofluoğlu¹, Yakup Sancar Barış², Erhan Emel¹

¹ Bakırköy Ruh Sağlığı ve Sinir Hastalıkları Eğitim ve Araştırma Hastanesi
² Ondokuzmayıs Üniversitesi Tıp Fakültesi

Özet

Son yıllarda, intrakranyal menenjiyomaları klinik ve radyolojik olarak taklit eden neoplastik ve non-neoplastik hastalıklar bildirilmektedir. Bu çalışmada, sol fronto-parietal, sağ frontal ve sağ oksipital bölgede yerleşim gösteren, birden çok intrakranyal kitlesi olan 57 yaşında kadın hasta sunulmaktadır. Bilgisayarlı tomografide iki taraflı saçlı deri erozyonları ve supratentorial epidural kitle görüntüsü saptanmış ve yapılan magnetik rezonans görüntüleme sonrasında, intrakranyal ve saçlı deride yerleşim gösteren birden çok sayıda menenjiyom ön tanısı konulmuştur. Hasta ameliyata alınarak sol fronto-parietal bölgedeki kitlesi başarı ile çıkarıldı. Histopatolojik inceleme tiroid folliküler karsinom metastazı olarak bildirildi. Bu çalışmada nadir görülen ve menenjiyoma olarak hatalı değerlendirilen, tiroid bezinin folliküler karsinomunun, intrakranyal metastaz ile ortaya çıkabileceği vurgulanmak istenmiştir.

Anahtar kelimeler: *Tiroid folliküler karsinomu, menenjiyoma takliti multipl menenjiyoma kafatası metastazı.*

Abstract

Recently, a number of neoplastic and nonneoplastic entities have been reported that radiographically and clinically mimic meningiomas. Because these lesions occur infrequently, and may resemble meningioma during intraoperative analysis, they may not be considered in the differential diagnosis. We report a case of a 57-year old woman presenting with multiple masses located in the left fronto-parietal, right frontal and occipital regions. The computed tomography showed skull erosions in the bilateral skull and the mass effect of supratentorial epidural hematoma. After magnetic resonance imaging (MRI), a suspected diagnosis of multiple meningiomas was made. The patient underwent surgery during which a lytic bone and an epidural mass in the left fronto-parietal region were encountered; the tumor was successfully resected through the employment of microsurgical techniques. Histological examination revealed a thyroid follicular neoplasm. The present case emphasizes that while the presence of such metastases are uncommon, multiple dural metastasis can be mistaken for multiple meningiomas in a differential diagnosis.

Keywords: *Thyroid follicular carcinoma, mimicking meningioma multiple meningioma skull metastasis.*

Introduction

The occurrence of neoplastic and nonneoplastic dural-based masses that mimic meningiomas has received little attention despite several recent reports^{1,2}. These occur rather infrequently, and such lesions may not be considered during intraoperative analysis². Postoperative recognition may also be challenging due to histological features which closely resemble variants of meningiomas². Breast, prostate, renal cell and thymic carcinoma mimicry cases have all been previously reported, but dural metastasis of follicular thyroid carcinoma is very rare^{3,4} and therefore less thoroughly investigated. Hereby we provide a case of dural metastasis of a follicular thyroid

carcinoma, which presented as a metastatic masses within the left frontoparietal, right frontal and right supratentorial regions, and was evaluated as a multiple meningioma during both the pre and peroperative phases. Awareness of the potential for metastasis of follicular thyroid carcinoma involving the dura may facilitate intraoperative recognition, and in some cases, prevent unnecessary additional surgery.

Case Report

A 57 year-old female patient was referred to our neurology clinic, complaining of a headache. Her neurological examination was evaluated as normal, but a slight scalp bulge was found in the left fronto-parietal region during the physical examination. In the cranial magnetic resonance imaging (MRI) taken thereupon, a densely contrast absorbing and space occupying lesion with 4x5x6 cm in the left fronto-parietal region, 1x1 cm in the right frontal region, 1x2x1.5 cm in the right occipital region, situated on the fornix of the tentorium was discovered, which was potentially radiologically concordant with meningioma. The patient was initially scheduled for the removal of the big mass in the left fronto-parietal region. During the operation, just after elevating the skin flap, it was observed that the whole fronto-parietal bone had been eroded by the mass which caused a bone defect approximately 5x2 cm in size, and the area surrounding the defect was densely vascular. After elevating the craniotomy flap, it was observed that the mass was extradurally located and invaded the outer tunica, but did not permeate the inner tunica and cerebral parenchyma. The tumoral mass was totally removed along with the dura. The eroded bone tissue was also excised, and the bone defect was closed by cranioplasty. After the operation, the two other masses found by MRI were scheduled to be removed. The pathological evaluation of the tumoral masses concluded that the patient was suffering from follicular thyroid carcinoma. Postoperative levels of thyroid hormones were normal, but radionuclide imaging with Tc-99 demonstrated a thyroid mass. The patient was referred to the oncology department for the further management of her primary and metastatic tumors, however, she refused any kind of treatment including adjuvant therapy or any other medical advice.

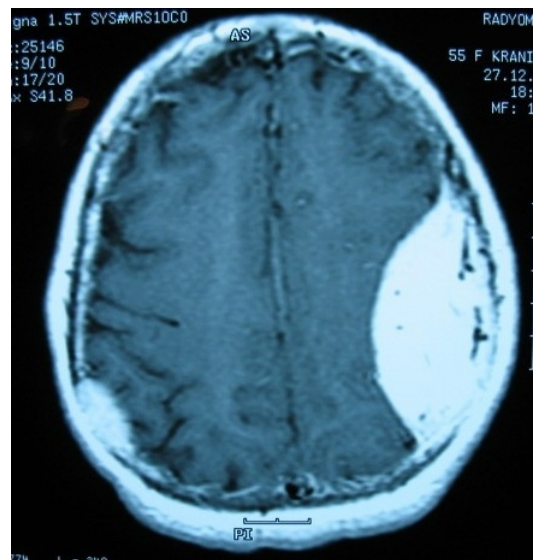


Figure 1

T1-weighted magnetic resonance imaging after gadolinium administration demonstrating a massive tumor in the epidural region extending to the left fronto-parietal lobe, as well as another small lesion in the right frontal cortex.

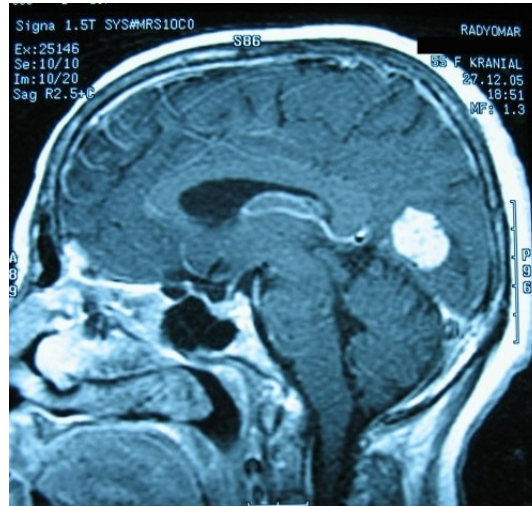


Figure 2

T-weighted MRI after gadolinium showing another lesion in the supratentorial occipital region.

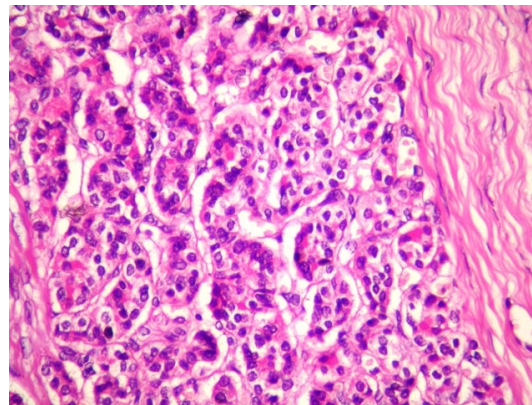


Figure 3

T-weighted MRI after gadolinium showing another lesion in the supratentorial occipital region.

Discussion

The incidence of thyroid carcinoma accounts for approximately 1% of all thyroid tumors. Follicular carcinoma accounts for 10–15% of clinically evident thyroid malignancies, and intracranial metastasis occurs in about 1% of these cases^{4,5}. The mean age of presentation was fifty to sixty years of age and preponderance in female patients was seen⁶. These statistics indicate the rarity with which intracranial metastasis occurs in patients with thyroid follicular carcinoma. Follicular thyroid carcinomas usually metastasize solitarily; no multiple intracranial metastases have been reported to date as far as we are aware. In our presented case, the patient presented with 3 metastatic lesions located in 3 different cerebral regions, both intracranial and extra-axial.

The spread of thyroid carcinoma is possibly hematogenous, involving both venous and arterial routes. More recently, arterial spread has also been suggested based on the association with secondary cutaneous locations in the territory of the ipsilateral external carotid artery⁷. This is also in accordance with the metastasis seen in our case.

Patients usually have a long clinical course before the diagnosis of skull lesion (mean 23.3 years) and the principal clinical feature is a palpable scalp mass. However, disturbance of consciousness, hemiparesis, headache,

cranial nerve dysfunction and exophthalmus have also all been reported as features of skull lesions ^{8,9}. Nevertheless, there are very few reports regarding the initial presentation of patients with distant metastasis leading to a diagnosis of follicular carcinoma ¹⁰⁻¹⁷. Emerick et al. reported two patients with distant metastasis at presentation ¹⁸. Sevinc et al. reported a rare, initial manifestation of a giant mass on the right scapula of a female patient ⁹. In our case, the intracranial masses were detected during the work up for the patient's headache.

The diagnosis in our case was difficult because the neuroimaging findings suggested that the principal suspect was multiple meningioma. Although meningiomas have well defined clinical and radiological features, there are reports that point out that other pathologies could simulate them ³. Dural metastases of follicular carcinoma initially interpreted as meningiomas have occasionally been reported ^{3,19}. Meningiomas are the most frequently seen as intracranial extra-axial space occupying lesions ¹. Sharp borders, dense and homogeneous contrast enhancement, hyperostosis in the adjacent bone and a dural tail are frequent MR and CT features of meningiomas, and these are important findings for the differential diagnosis of the dura based metastatic lesions. These imaging findings may allow for the confusion of meningiomas with cranial extra-axial masses at the first glance. MR spectroscopy, an imaging method, may be an effective alternative tool to help in the radiological diagnosis of the lesion. The lactate peak associated with the meningioma in MR spectroscopy is an important pathognomonic factor, while different lipid signals are an important finding for metastasis ³.

Anatomically, skull metastatic lesions are most frequently located over the occipital region, but isolated papers report lesions located over the sellar region, posterior fossa, and skull base ¹¹⁻¹³. Skull metastatic lesions were found to be osteolytic by CT scan, and highly vascular upon MRI assessment ⁸. The osteolytic and highly vascularized nature of the lesion is consistent with our findings in this case. However, there were two different, definite tumors, which caused the lytic bone lesions, one right in the frontal region, and a second in the left fronto-parietal region.

The best treatment for skull metastasis remains to be determined, but current literature favors excision of the skull lesion, thyroid tissue ablation and TSH-suppressive maintenance dosing with L-thyroxine. Only 17% of metastatic lesions to the brain take up iodine-131, so the effectiveness of radioactive ablation on brain metastasis is very restricted. This suggests that excision is the optimal treatment for metastatic brain tumor from follicular thyroid carcinoma defined by radical and maximal excision followed by thyroid hormone supplementation and radioactive ablation using iodine-131 for the untreated primary lesion ^{9,3}.

Dura based metastases of the follicular thyroid carcinoma are rare. However, metastatic follicular thyroid carcinoma should be kept in mind in the differential diagnosis of multiple intracranial dura-based masses. It is crucial to utilize advanced imaging examinations when the presence of multiple masses is determined, and a differential diagnosis of metastatic and primary brain tumors should be considered.

References

1. Rodriguez LE, Rodriguez CY, Cardozo DP, Molina OM, Cardozo JJ. The classical clinical and neuroimaging features of meningiomas are mimicked by other intracranial, supratentorial expansive lesions. *Rev Neurol* 1999;30: 907-910
2. Johnson MD, Powell SZ, Boyer PJ, Weil RJ, Moots PL. Dural lesions mimicking meningiomas. *Hum Pathol* 2002;33(12):1211-26
3. Tagle P, Villanueva P, Torrealba G, Huete I. Intracranial metastasis or meningioma? Uncommon clinical diagnostic dilemma. *Surg Neurol* 2002;58(3-4): 241-5.
4. Kleinschmidt-DeMasters BK. Dural metastases: a retrospective surgical and autopsy series. *Arch Pathol Lab Med* 2001;125: 880-887.
5. Venkatesh S, Leavens ME, Samaan NA. Brain metastases in patients with well-differentiated thyroid

- carcinoma: study of 11 cases. *Eur J Surg Oncol* 1990;16: 448–450
6. Ogawa Y, Sugawara T, Seki H, Sakuma T. Thyroid follicular carcinoma metastasized to the lung, skull, and brain 12 years after initial treatment for thyroid gland: case report. *Neurol Med Chir (Tokyo)* 2006;46: 302–305.
 7. Sgouros S, Walsh AR. Synchronous dural and cutaneous metastasis along the distribution of the external carotid artery. *Br J Neurosurg* 1994;8: 617–619.
 8. Nagamine Y, Suzuki J, Katakura R, Yoshimoto T, Matoba N, Takaya K. Skull metastasis of thyroid carcinoma. Study of 12 cases. *J Neurosurg* 1985;63: 526–531
 9. Sevinc A, Buyukberber S, Sari R, Baysal T, Mizrak B. Follicular thyroid cancer presenting initially with soft tissue metastasis. *Jpn J Clin Oncol* 2000;30(1): 27–29.
 10. Inci S, Akbay A, Bertan V, Gedikoglu G, Onol B. Solitary skull metastasis from occult thyroid carcinoma. *J Neurosurg Sci* 1994;38: 63–66
 11. Ruchti C, Balli-Antunes M, Gerber HA. Follicular tumor in the sellar region without primary cancer of the thyroid. Heterotopic carcinoma? *Am J Clin Pathol* 1987;87: 776–780
 12. Song IS, Chan KF, Tey PH, Choi HS. An unusual case of thyroid carcinoma metastasis to the posterior fossa. *Mt Sinai J Med* 1981;48(3): 281–285
 13. Rosahl KS, Erpenbeck V, Vorkapic P, Samii M. Solitary follicular thyroid carcinoma of the skull base and its differentiation from ectopic adenoma-review, use of galectin-3 and report of a new case. *Clin Neurol Neurosurg* 2000;102:149–155.
 14. Shaha AR, Shah JP, Loree TR. Differentiated thyroid cancer presenting initially with distant metastasis. *Am J Surg* 1997;174(5): 474–476
 15. Caldero'n-Garciduen~as AL, Gonza'lez-Schaffinni MA, Farias-Garcia R, Rey-Laborde R. Cranial metastasis of thyroid follicular carcinoma. Report of a case. *Gac Med Mex* 2001; 137(4): 356–360
 16. Ozdemir N, Senoglu M, Acar UD, Canda MS. Skull metastasis of follicular thyroid carcinoma. *Acta Neurochir (Wien)* 2004;146(10):1155–1158
 17. Boehm T, Rothouse L, Wartofsky L. Metastatic occult follicular thyroid carcinoma. *JAMA* 1976;253: 2420–2421.
 18. Emerick GT, Duh QY, Siperstein AE, Burrow GN, Clark OH. Diagnosis, treatment and outcome of follicular thyroid carcinoma. *Cancer* 1993;72: 3287–3295.
 19. Yodonawa M, Tanaka S, Kohno K, Ishii Z, Tamura M, Ohye C. Brain metastasis of follicular carcinoma of the thyroid gland. Meningioma-like features demonstrated by CT scan and cerebral angiography: case report. *Neurol Med Chir (Tokyo)* 1987;27(10): 995–999.