

Synchronous Colon and Breast Cancer: A Case Report

Senkron Kolon ve Meme Kanseri: Olgu Sunumu
Genel Cerrahi

Başvuru: 13.11.2020
Kabul: 21.03.2021
Yayın: 30.04.2021

Mevlüt Recep Pekçici¹, Abdullah Şenlikci¹, Marlen Süleyman¹, Koray Koşmaz², Abdullah Durhan¹

¹ Ankara Eğitim ve Araştırma Hastanesi

² Türkiye Yüksek İhtisas Eğitim ve Araştırma Hastanesi

Özet

Senkron solid tümörlerin tedavisine multidisipliner bir onkoloji konseyinde karar verilmelidir. 67 yaşında kadın hasta sağ memede kitle ve rektal kanama nedeniyle genel cerrahi polikliniğine başvurdu. Konsey, mamografide BIRADS 5 lezyonu ve kolonoskopide rektosigmoid bileşkede kitle görülmesi üzerine ameliyat kararı aldı. Hastaya önce modifiye radikal mastektomi ve 1 ay sonra anterior rezeksiyon uygulandı. Hasta 7 yıl sonra tümör dışı nedenlerden öldü. Meme kanseri ve kolon kanseri nadiren eş zamanlı olarak görülür. Cerrahi öncelikle morbiditesi düşük olana uygulanmalıdır. Efektif tedavi ile sağkalım, tek bir primer tümörü olan vakalardan daha kötü değildir.

Anahtar kelimeler: senkron tümör, kolon kanseri, meme kanseri

Abstract

Treatment of synchronous solid tumors should be decided in a multidisciplinary oncology council. A 67-year old female patient was admitted to the general surgery outpatient clinic due to a mass in the right breast and rectal bleeding. The council made a decision for surgery as a BIRADS 5 lesion was observed on mammography and a mass in the rektosigmoid junction was observed on colonoscopy. First, the patient underwent a modified radical mastectomy and 1 month later, anterior resection. The patient died 7 years later from non-tumoral causes. Breast cancer and colon cancer are rarely observed synchronously. Surgery should be performed primarily on the one with lower morbidity. With effective treatment, survival is no worse than for cases with a single primary tumor.

Keywords: Synchronous tumor, colon cancer, breast cancer

Introduction

Management of solid tumors in different synchronous locations is an interesting clinical scenario. To which tumor intervention should first be made and how to continue treatment is decided according to the independent risk of each tumor. In these cases, it is necessary to act with a multidisciplinary team consisting of an oncologist, surgeon, radiologist and pathologist¹.

The case is here presented of a patient treated and followed for synchronous colon and breast cancer with the approaches discussed in the light of the relevant literature.

Case Report

A 67-year old female patient was admitted to the general surgery outpatient clinic due to complaints of a mass in the right breast, rectal bleeding and weight loss. On physical examination, a mass approximately 2 cm in size was determined in the right breast. On mammography, a 15x25 mm-sized BIRADS-5 lesion was observed in the right upper quadrant of the right breast. The biopsy result was evaluated as invasive ductal carcinoma. Progesterone

and estrogen receptors were evaluated as positive and the C-erb-B2 result as negative. On colonoscopy examination, a mass was observed in the rectosigmoid junction (Figure 1).

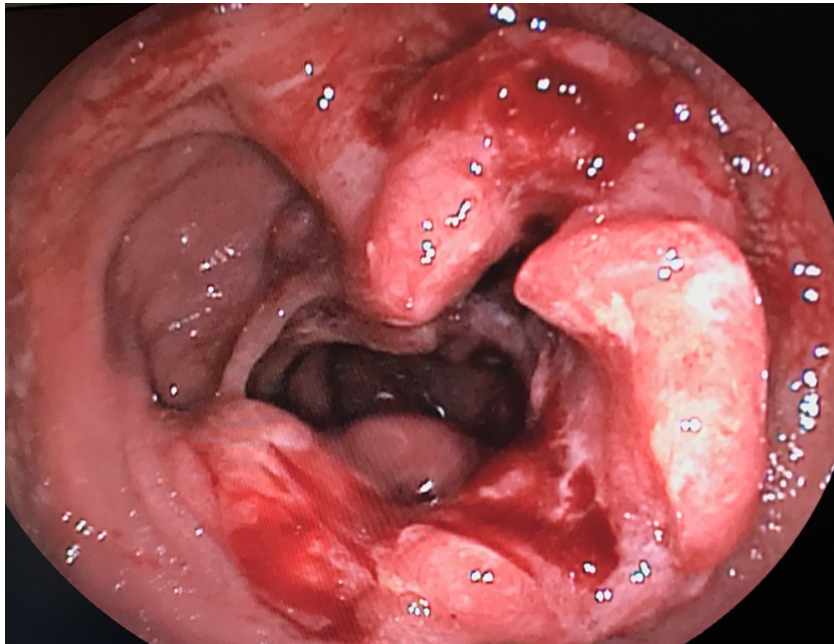


Figure 1
Colonoscopic view of the lesion

The histopathology result was evaluated as adenocarcinoma. No metastasis was detected on thorax and abdominal tomography. Bone scintigraphy showed no appearance compatible with metastasis. The carcinoembryogenic antigen level was 1.19 µg / L, and the cancer antigen 125 value was 9.3 kU / L. The decision for surgery was taken by the multidisciplinary tumor board. The patient underwent a right modified radical mastectomy. Anterior resection and colocolonic anastomosis were performed after 1 month due to colon cancer. No complications were observed after either operation, and the patient was discharged on the 7th day after colon surgery. The breast histopathology examination was reported as invasive ductal carcinoma. Progesterone and estrogen receptors were evaluated as positive and the C-erb-B2 result was negative. The pathological stage was T2N0M0 according to TNM-8, and stage IIA. In the histopathology report of the colon cancer, it was evaluated as T4aN2b and stage IIIC.

Case Discussion

Multiple primary cancers represent 16% of new cancer diagnoses². The study of Liu et al. showed a 7% prevalence³. Most of these are diagnosed with two primary cancers, but in the literature, there are reported cases of three, four and five cancers in the same patient². It is difficult to explain the synchronous observation of breast cancer and colorectal cancer through metallothioneins because down-regulation is observed in colorectal cancer while overexpression is observed in breast cancer. There is no known factor for tumorigenesis between these two tumors⁴, although a family history of cancer may be a determining factor in synchronous cancers⁵. In a study by Kimura et al., family history was shown to be a determining factor for synchronous cancer⁶. Peutz-Jeghers syndrome has been associated with colon and breast cancer, with multiple hamartomatous polyps in the small intestine and mucocutaneous hyperpigmentation⁵. In the current case, there were no factors indicating the possibility of Peutz-Jeghers syndrome.

Since there is no specific consensus guideline for synchronous tumors, treatment is applied according to the decision of the multidisciplinary tumor council. The prognosis of synchronous tumors is evaluated separately according to the stage of each tumor. If managed correctly, the prognosis of these types of cases is no worse than for single primary tumors⁷. To be able to perform the next surgery in as short a time as possible, the tumour with lower morbidity should be operated on first⁸. In the current case, modified radical mastectomy was performed primarily as that has lower morbidity and there was no ileus in this case. The treatment applied for both malignancies was seen to be effective, and 7-year survival was observed.

In conclusion, breast cancer and colon cancer are rarely observed synchronously. Since there is no specific treatment algorithm, treatment should be decided by a multidisciplinary oncology council. Surgery should be performed primarily on the tumour with lower morbidity, and when an effective treatment plan is implemented, survival is no worse than for a single malignancy.

References

1. Higgins L, et al. Synchronous breast and colon cancer: factors determining treatment strategy. *BMJ Case Rep.* 2013;2013:bcr2013009450.
2. Markakis C, et al. Multiple synchronous primary neoplasms of the breast, colon and rectum after surgery for endometrial cancer: A case report. *Int J Surg Case Rep.* 2013;4(5):493-5.
3. Liu L, et al. Prevalence of multiple malignancies in the Netherlands in 2007. *International Journal of Cancer* 2011;128(7):1659–67.
4. Jafferbhoy S, Paterson H, Fineron P. Synchronous gist, colon and breast adenocarcinoma with double colonic polyp metastases. *Int J Surg Case Rep.* 2014;5(8):523-6.
5. Ari A, et al. Synchronous male breast and colon cancer presenting with ileus: A case report. *Int J Surg Case Rep.* 2016;28:31-3.
6. Kimura T, et al. Synchronous colorectal carcinomas. *Hepatogastroenterology.* 1994;41(5):409-12.
7. Abdulla HA, Almarzooq R, Alrayes A. Synchronous breast and colon cancer: the importance of multidisciplinary team cancer meetings. *BMJ Case Rep.* 2019;12(12):e232680.
8. Yetkin G, et al. Synchronous Occurrence of Primary Breast Carcinoma and Primary Colon Adenocarcinoma. *Case Rep Surg.* 2017;2017:7048149.