

## Perforation due to Foreign Body in Incarcerated Incisional Hernia

İnkarsere İnsizyonel Hernide Yabancı Cisime Bağlı Perforasyon  
Genel Cerrahi

Başvuru: 24.08.2019  
Kabul: 05.10.2019  
Yayın: 28.01.2020

Ersin Kılıç<sup>1</sup>, Sertaç Ata Güler<sup>1</sup>, Ceylan Kiy<sup>1</sup>, Turgay Şimşek<sup>1</sup>, Nihat Zafer Utkan<sup>1</sup>

<sup>1</sup> Kocaeli Üniversitesi Tıp Fakültesi

### Özet

Gastrointestinal sistemin yutulan yabancı cisimlere bağlı perforasyonu farklı klinik tablolarla kendini gösterebilir ve operasyon öncesi doğru tanı nadiren konulur. Olgumuzda inkarsere insizyonel herniye ikincil incebağırsak perforasyonu ön tanısıyla opere edilen hastada strangülasyon olmadan yabancı cisme bağlı (tavuk kemiğine) perforasyon saptadık. İnkarsere barsak segmenti içindeki olası bir yabancı cismin trakt içerisinde oluşan angulasyon nedeniyle ilerleyememesi durumunda barsak duvarında ülserasyon ve perforasyona sebep olabileceği unutulmamalıdır. Hastaların çekilen bilgisayarlı tomografilerinde herniye alanın içinde yabancı cisim olabileceği düşünülerek dikkatlice yorumlanmalıdır.

**Anahtar kelimeler:** *İnce barsak perforasyonu, İnkarsere insizyonel herni, Tavuk kemiği, Yabancı cisim*

### Abstract

Perforation of the gastrointestinal tract due to ingested foreign bodies may manifest itself with different clinical signs or symptoms and correct diagnosis is rarely performed before the operation. In our case, we detected a perforation due to foreign body (chicken bone) without strangulation in a patient who was operated with the preliminary diagnosis of small intestinal perforation secondary to incisional hernia. It should be kept in mind that a possible foreign body inside the incarcerated bowel segment can cause ulceration and perforation in the bowel wall if it cannot progress due to the angulation occurring in the tract. The computed tomography scans of the patients should be interpreted with caution since there may be a foreign body within the herniated area.

**Keywords:** *Small bowel perforation, Incarcerated incisional hernia, Chicken bone, Foreign body*

### Introduction

A large proportion of ingested impurities are usually excreted out of the gastrointestinal tract spontaneously without causing any problems. Small bowel perforation due to foreign bodies is a rare clinical finding and occurs in less than 1% of patients<sup>1</sup>. As swallowing a foreign body is often accidental, it is difficult to diagnose. Intentionally swallowing a foreign body is more frequently seen in psychiatric patients<sup>2</sup>. However, in a small proportion of patients who ingest foreign bodies, complications such as perforation or ileus due to impaction may develop<sup>3,4</sup>. A 65-year-old male patient with incarceration due to the intestinal perforation who was operated with the diagnosis of a foreign body attachment (chicken bone) without strangulation is presented.

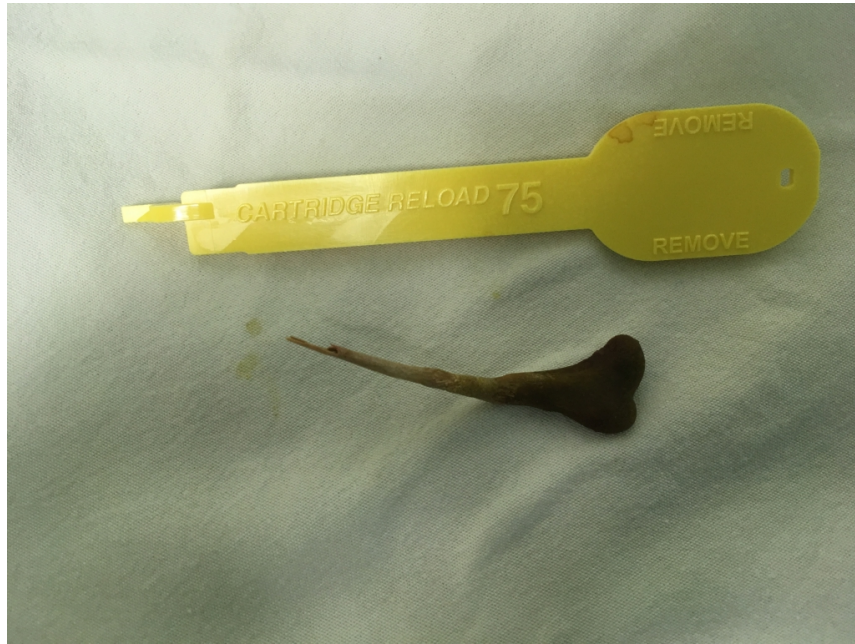### Case Report

A 65-year-old male patient presented to the emergency department with complaints of aggravated pain and nausea and vomiting after sudden onset of abdominal pain. Patient had a history of incisional hernia due to ileus-related colon resection and follow-ups. It was learned that there was swelling in the incision area for about 2 years. The patient's vital signs were 38.2 ° C fever, 110 / min heart rate, and 25 / minute breathing. The patient with tachycardia, tachypnea and fever, had tenderness, defenses and rebound in the abdominal examination, especially in the region that had muscle-fascia defect in the incision area. Intestinal loops in the hernia area were incarcerated and could not be reduced. White blood cell count was 13.026x10<sup>3</sup> /L, CRP: 32.2 mg / dl and Hgb:

Corresponding Author: Ersin Kılıç , Umuutepe /KOCAELİ  
dr.ersinklc90@gmail.com

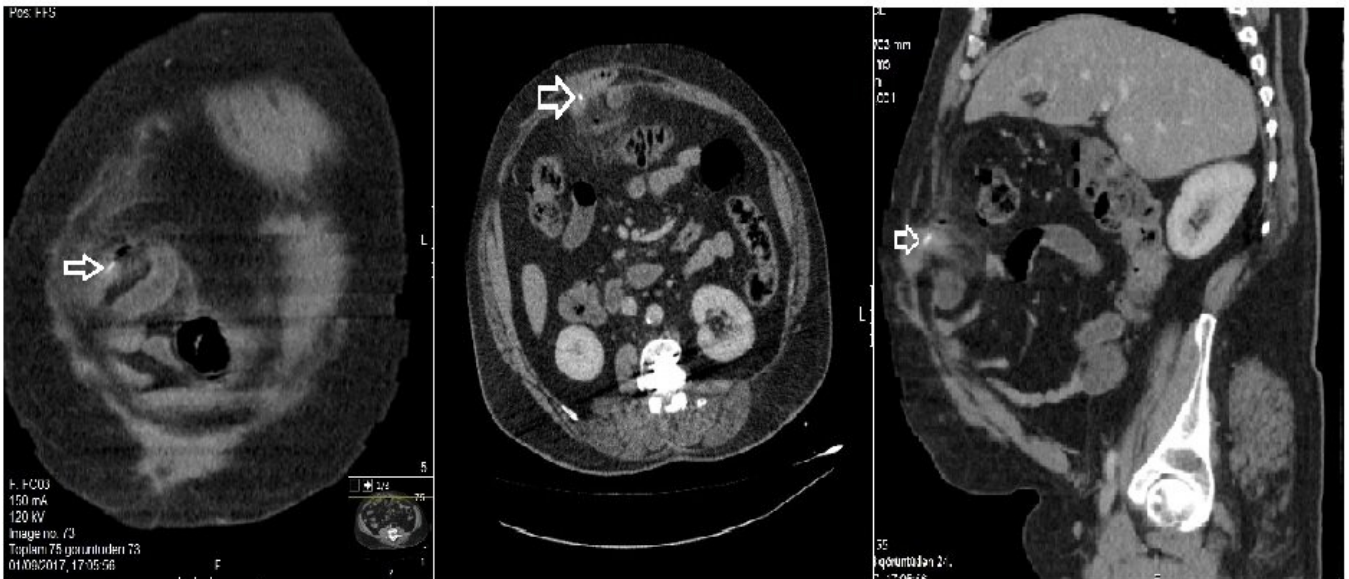
Kılıç E ve ark . İnkarsere insizyonel hernide yabancı cisime bağlı perforasyon. CausaPedia. 2020; 9(1): 24-27.

12.7 g / dl. Biochemistry values were within normal limits. In the abdominal computed tomography of the patient with intravenous contrast, an abdominal obstruction was seen at the superior surface of the umbilicus at the 2 sides of the abdominal wall and the hernia under the skin was observed. Correlated doppler showed strangulated herniated bowel loops in ultrasound examination and free air and fluid values were observed in the abdomen. The patient was thought to have perforated strangulated bowel and was decided that he should undergo an emergency surgical exploration. In the exploration, purulent fluid and diffuse adhesions were observed inside the hernia sac and in the abdomen. There was perforation in the bowel of the hernia. In this area, a foreign body was seen as a chicken bone (Figure 1).



**Figure 1**  
chicken bone

It was decided that the perforation in the bowel was due to the foreign body. After the perforated area was resected, it was repaired by side-to-side with anastomosis. The hernia defect was repaired primarily without patching. Postoperatively, when the patient's abdominal computed tomography was taken to the emergency department, a foreign body was observed in herniated area (Figure 2).



**Figure 2**

Foreign body (chicken bone) appearing in bowel loops on computed tomography sections

The patient was discharged from the hospital on the 8th postoperative day after gradual regeneration of the regimen due to the lack of significant return from the drains on the postoperative 5th day.

## Case Discussion

It is defined as herniation of the organs of the gastrointestinal tract out of the abdominal compartment. This condition can cause normal anatomy to be impaired by decreasing blood supply and narrowing of the gastrointestinal tract and slowing the passage<sup>6</sup>. Inadvertent swallowing of foreign bodies is common in childhood, but can be seen in all age groups. It is an emergency condition especially in adults with psychiatric disorders<sup>2</sup>. The most important result of this condition is gastrointestinal perforation. The most common cause of perforation of the gastrointestinal tract is swallowing foreign bodies like fish bones, chicken bones, and sharp objects such as toothpicks<sup>1,3</sup>. Complications due to foreign body ingestion may not be diagnosed by routine physical examination and standard diagnostic methods. Patients may present with localized or extensive peritonitis, abdominal mass or abscess<sup>2</sup>. The most common radiological finding is free air in the abdomen after perforation, ileus and acute abdomen<sup>2</sup>.

Sometimes foreign bodies can progress through the intestinal tract and can be removed by defecation. However, during normal progression, they may cause ulceration or perforation if they coincide with narrowed areas such as secondary to herniation<sup>5</sup>. In our case, the patient developed an acute abdomen due to the fact that the chicken bone that he swallowed without noticing could not progress in the narrowed area of the bowel segments within the existing incarcerated hernia sac, and perforated the area.

In conclusion, the reason of perforation in patients with acute abdominal pain is not always strangulation. It should be kept in mind that a possible foreign body in the incarcerated bowel segment can cause ulceration and perforation in the bowel wall if it cannot progress due to the angulation occurring in the tract. The computed tomography scans of the patients, should be interpreted with caution since it may be a foreign body within the herniated area.

## Special Thanks

We wish to thank Ömer Yavuz and Gökhan Pösteki for their contribution to the paper.

## References

1. Mutlu A, et al. A fish bone causing ileal perforation in the terminal ileum. *Ulus Travma Acil Cerrahi Derg.* 2012 Jan;18(1):89-91.
2. Lunsford KE, Sudan R. Small bowel perforation by a clinically unsuspected fish bone: laparoscopic treatment and review of literature. *J Gastrointest Surg.* 2012;16(1):218-22.
3. Velitchkov NG, Grigorov GI, Losanoff JE, Kjossev KT. Ingested foreign bodies of the gastrointestinal tract: retrospective analysis of 542 cases. *World J Surg* 1996;20(8):1001-5.
4. Goh BK, et al. Perforation of the gastrointestinal tract secondary to ingestion of foreign bodies. *World J Surg.* 2006;30(3):372-7.
5. Tay GC, Chng JK, Wong WK, Goh YC. Chicken bone perforation of an irreducible inguinal hernia: a case report and review of the literature. *Hernia.* 2013;17:805-7.
6. Kulah B, et al. (2001) Presentation and outcome of incarcerated external hernias in adults. *Am J Surg.* 2001; 181:102-4.

## Information Presentation

21st National Surgery Congress, 11 - 15 April, 2018, Kaya Palazzo & Kaya Riu Congress Center, Antalya, Turkey