

Giant Mature Cystic Teratoma manifested as an Intraabdominal Mass

Karın İçi Kitle Olarak Kendini Gösteren Matür Kistik Teratom
Kadın Hastalıkları ve Doğum

Başvuru: 07.08.2018
Kabul: 20.08.2018
Yayın: 17.09.2018

Hayal Şimşek¹, Sertaç Ata Güler¹, Turgay Şimşek¹, Yiğit Çakıroğlu¹, Saliha Yeşim Gürbüz¹, Nihat Zafer Utkan¹

¹ Kocaeli Üniversitesi Tıp Fakültesi

Özet

Nadir görülen dev olgun kistik teratom tanısı konan bir olgu sunmayı amaçladık. Progresif dispne ve abdominal şişlik şikayeti ile başvuran 32 yaşındaki bir kadın hastanın fizik muayenesinde ksifoid üzerinde bir kitle palpe edildi. X-ray görüntülemeye diyafram eleve görünümdeydi. Ultrasonografide, abdomende orta hat pozisyonunu kaplayan ve pelvise kadar uzanan, anekoik kistik lezyon tanımlandı. İntraabdominal kitle ön tanısı ile araştırılan hastanın tüm karını kaplayan 30 cm'den büyük kitle lezyonları sol salfenks ile birlikte tamamen eksize edildi. Operasyon esnasında çalışılan frozen kesit incelemede, kitle, teratom olarak bildirildikten sonra operasyon sona erdi. Muhtemel doğurganlık problemleri, azalan yumurtalık rezervi ve bilateral ovaryan teratom gelişimi riski, over koruyucu tümör cerrahisinin popülaritesini artırmıştır.

Anahtar kelimeler: *üremenin korunması, over neoplazmları, teratom*

Abstract

We aimed to present a case diagnosed with a rarely seen giant mature cystic teratoma. A solid mass lying up to xiphoid was palpated during the physical examination of a 32 year old, female patient who referred to us with the complaint of progressive dyspnea and abdominal swelling. Diaphragm was elevated on x-ray, a hydatid cyst that occupied a midline position in the abdomen lying down to the pelvis and an anechoic cystic lesion without a differential diagnosis were described on ultrasonography. The mass lesion was over 30cm that occupied the entire abdomen of the patient. She was explored with a prediagnosis of intra-abdominal mass that was excised with left salpinx and intact totally. The operation was ended after the mass was diagnosed as a teratoma by frozen section analysis. The increased risk of possible fertility problems, diminished ovarian reserve and bilateral ovarian teratoma development have increased the popularity of ovary-preserving tumor surgery.

Keywords: *fertility preservation, ovarian neoplasms, teratoma*

Introduction

As 15% of all ovarian tumors are composed of teratomas, approximately 95% of teratomas are composed of mature cystic teratomas. Teratomas are tumors that originate from multiple germ layers and may consist multiple cell types. In general, the predominant germ layer is ectoderm. Several tissues including primarily skin and skin appendages develop from this layer¹. While the majority of the cases do not cause any symptoms and indications, the most frequently encountered symptoms are abdominal pain and abdominal swelling². Graphy, ultrasonography, computed tomography or magnetic resonance imaging (MRI) can be used for diagnosis³. The treatment after the diagnosis is towards surgical resection. The treatment for mature teratomas have been oophorectomy until today. However, the increased risk of possible fertility problems, diminished ovarian reserve and bilateral ovarian teratoma development have increased the popularity of ovary-preserving tumor surgery⁴. Since, the patients are generally within reproductive period and fertile, care must be taken to remove just the tumor instead of removing the total ovary^{5,6}. In this report, a case of a giant mature cystic teratoma detected in a 32-year old female patient was presented.

Case Report

A 32-year old, single, female patient referred to us with the complaint of progressive dyspnea and a progressive swelling in the abdomen. A solid, semi-mobile mass around 30x25 cm that lies up to xiphoid process was palpated during the physical examination (Figure 1a,b,c).

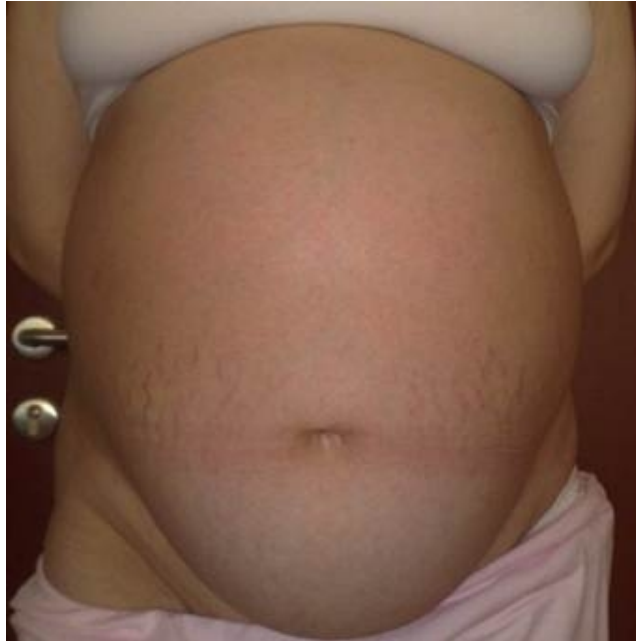

Figure 1A

The preoperative frontal abdominal appearance of the patient with an intraabdominal cyst that lies up to xiphoid level with a size similar to a 38-week pregnancy.

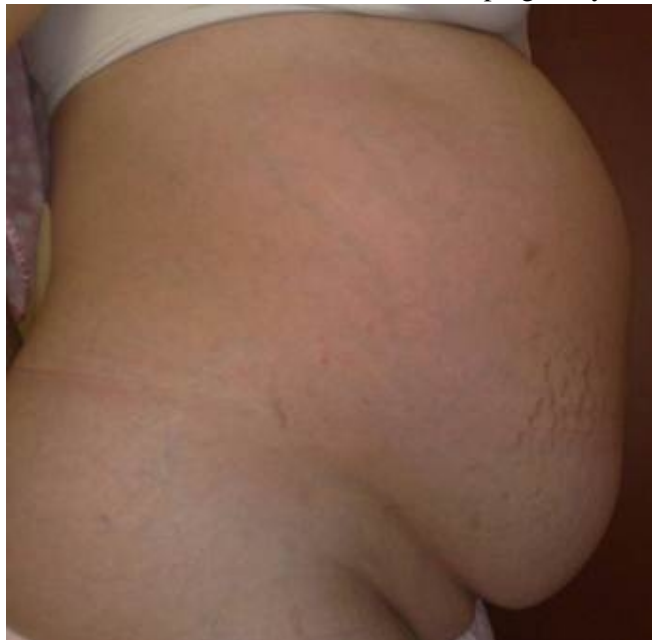

Figure 1B

The preoperative lateral abdominal appearance of the patient with an intraabdominal cyst that lies up to xiphoid level with a size similar to a 38-week pregnancy.

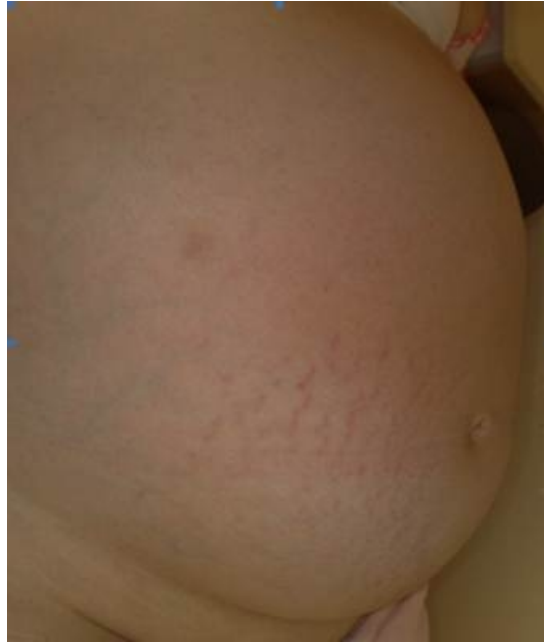

Figure 1C

The preoperative frontolateral abdominal appearance of the patient with an intraabdominal cyst that lies up to xiphoid level with a size similar to a 38-week pregnancy.

Hemogram and biochemical parameters and tumor markers were within normal limits. Diaphragm was observed elevated on the right side in chest x-ray (Figure 2).

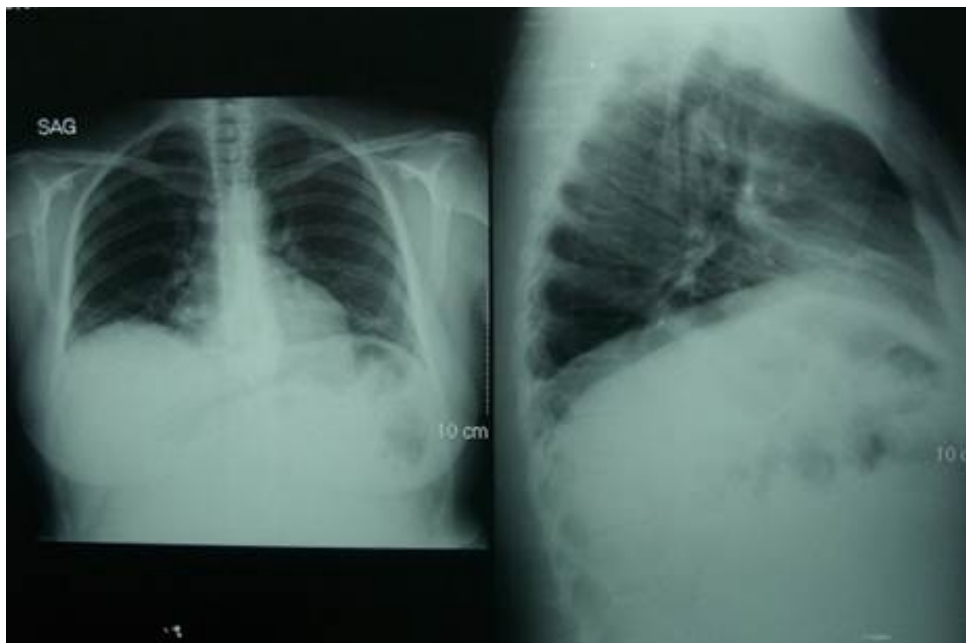


Figure 2

Elevated to diaphragm on right side in PA and lateral chest x-ray.

A 260x149 mm hydatid cyst that occupies the midline of the abdomen and lies down to pelvis and an anechoic cystic lesion without a differential diagnosis were described in ultrasonography (Figure 3).

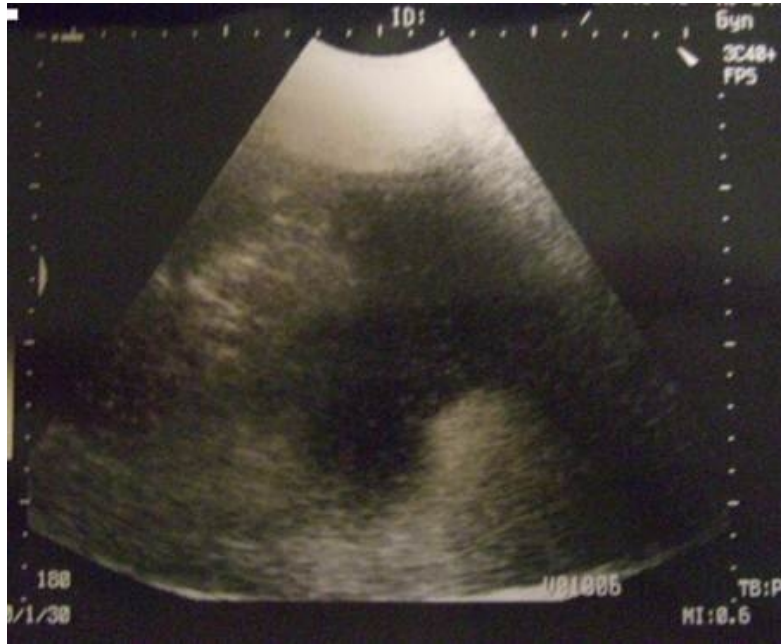

Figure 3

A 260x149 mm hydatid cyst that occupies the midline of the abdomen and lies down to pelvis and an anechoic cystic lesion without a differential diagnosis were described in ultrasonography

No ascites was observed. On MRI, a cystic mass that occupied the entire abdomen was detected in the midline of the abdomen and it appeared as a mesenteric cyst, cystic lymphangioma or hydatid cyst in differential diagnosis (Figure 4 a,b,c).

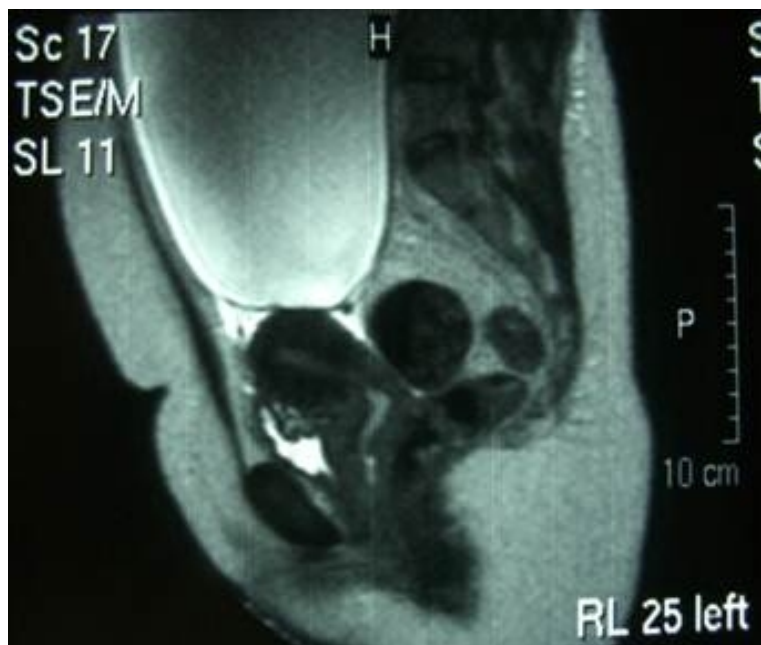

Figure 4A

Cystic mass that appeared as a mesenteric cyst, cystic lymphangioma and hydatid cyst in differential diagnosis and occupied the midline of the abdomen in the sagittal section on magnetic resonance imaging.

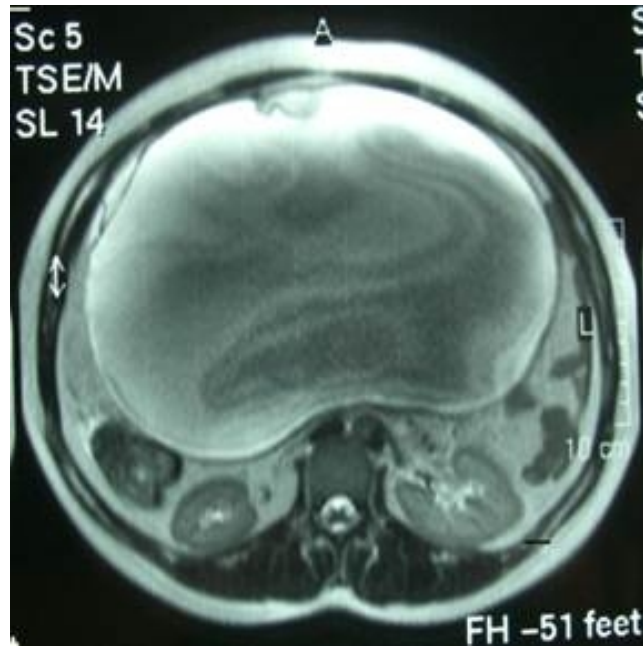


Figure 4B

Cystic mass that appeared as a mesenteric cyst, cystic lymphangioma and hydatid cyst in differential diagnosis and occupied the midline of the abdomen in the transverse section on magnetic resonance imaging.

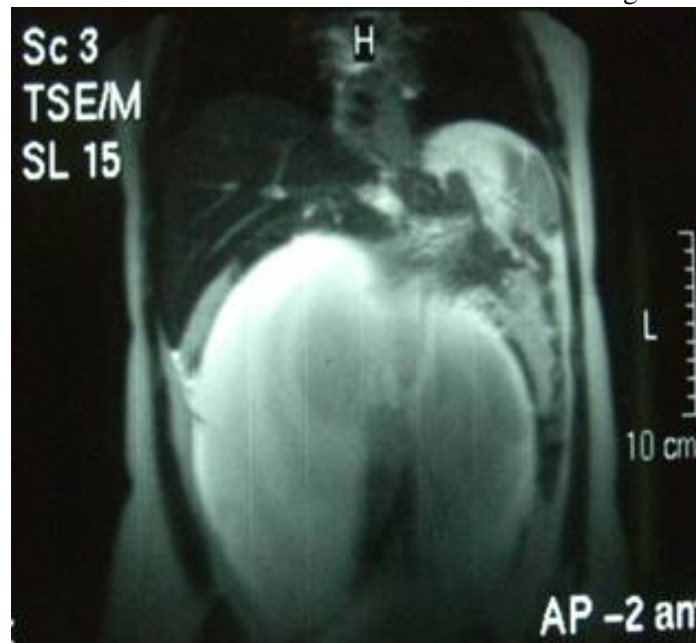

Figure 4C

Cystic mass that appeared as a mesenteric cyst, cystic lymphangioma and hydatid cyst in differential diagnosis and occupied the midline of the abdomen in the coronal section on magnetic resonance imaging.

Echinococcus indirect hemagglutination (IHA) was determined as negative in the patient serology. A mobile, smooth-contoured mass lesion lay between the pelvis and the diaphragm and occupied the entire abdomen of the patient. She was explored by laparotomy after a prediagnosis of abdominal mass. The uterus and right adnexal structures appeared normal. The lesion was excised totally with the left salpinx. The operation was ended after the diagnosis of a teratoma by frozen section analysis. The postoperative pathology of ten kg and 31x27x13 cm cystic mass was reported as “mature cystic teratoma containing cartilage and fat tissue on the cyst wall in its sections”. Postoperatively, the patient was followed-up for 24 months without any problems.

Case Discussion

In this case report, a giant mature cystic teratoma was detected in a 32-year old female patient who referred to our clinic because of dyspnea and progressive swelling of the abdomen. The most important aspect of this case is the size of the tumor. Being the most common benign tumor in women under the age of 20, it can be observed in all age groups of reproductive period^{6,7}. While mature cystic teratomas generally appear as single-sided, it was stated that it might occur as double-sided in 8-15% of the cases. The cysts that originated from the ovary were evaluated as big cysts for over 5 cm and as giant cysts for over 15 cm⁸. Some authors have described the cysts that are above the umbilicus level as giant cysts⁹. Mature cystic teratoma cases above 30 cm are very rare. In our case, though the mass reached up to giant dimensions, it was single-sided and no pathology was observed in the other ovary. Similarly, Devoize et al., described a giant mature cystic teratoma about 32x27x18.5 cm in size¹⁰. As distinct from ours, more than 300 teeth were detected in their case.

Mature cystic teratomas are generally asymptomatic and they present symptoms when there is an increase in their size. They refer frequently with pubic or abdominal pain. A case was also observed where an infected dermoid cyst encountered as an appendix abscess was fistulized to transverse colon¹¹. In our case, the dyspnea complaint of the patient was at the forefront despite there was a distension in the abdomen. It was thought that this condition has occurred due to the lack of chest expansion as a result of the compression of the growing mass on the diaphragm. Among the ovarian cysts, teratomas are the ones which are often associated with torsion and infection¹². In cases of teratoma, complications such as torsion, rupture and infection can be encountered¹³. It was indicated that torsion and rupture are the most frequent ones². While malignant transformation ratio was 1-2% in mature teratomas of the ovary, it was stated that this condition occurred mostly throughout the postmenopausal period^{7,14,15}. Squamous cell carcinoma was observed most commonly with a ratio of 75%¹⁴. Although, the presence of increased solid component in the MRI is helpful, it is difficult to distinguish their malignancy preoperatively¹⁶⁻¹⁹. In case of suspecting from a malignancy preoperatively, intra-operative consultation and postoperative histological examination become important²⁰.

An increase in Ca 125 and Ca 19-9 levels are expected in these tumors. Especially in cases above 10 cm, Ca 19-9 levels were found higher^{6,21,22}. It was pointed out that the tumor size and adhesion ratio were higher in patients with an increased Ca 19-9, and Ca 125 was in rise²³. According to the study by Kataoka et al., the highest Ca 19-9 level among ovarian masses was detected in a bilateral mature cystic teratoma case²¹. Ca19-9 is probably the most valuable marker for dermoid cysts compared to the other tumor markers²². In addition, it should be noted that these levels may decrease during postoperative period²³.

Tearing of the tumor capsule does not negatively affect the prognosis in general. Again, chemical peritonitis, dispersion of tumor cells and recurrence should be avoided²⁴. In our case, torsion or rupture was not observed as a complication despite the size of the mass was big; and it could be removed out of the abdomen easily by dissecting from the surrounding tissue perioperatively. Based on the study by Târcoveanu et al., it was suggested that laparoscopic surgery was a safe and effective management in ovarian teratoma cases and the complication rate was similar to laparotomy⁶. Although, the advantages such as good cosmetic outcome, rapid recovery, less pain and short-term hospitalization are present in laparoscopic management, it should be noted that the exposure is difficult, operative field may be narrow and thus, cyst rupture may occur during trocar entry especially in the masses greater than 10 cm^{8,25}. Therefore, decompression by aspiration is required to remove the cysts greater than 10 cm with this technique^{6,26}. Also, in another study, it was pointed out that when the dermoid cyst is ruptured during laparoscopic management, it should be washed with ringer lactate and drained for 24-48 hours in order to decrease the probability of chemical peritonitis²⁷.

In our case, laparotomy was planned by a team of general surgeons and gynecologists due to the probability of malignancy and dyspnea. In conclusion, giant ovarian masses should be excised by the most appropriate surgical

procedure to the patient because of the symptoms related to compression, the difficulty in the detection of the mass origin and the presence of malignancy possibility; and the ovarian reserve should be preserved as much as possible⁸. Therefore, more research is required to determine the most appropriate diagnosis, management and follow-up protocols for these patients.

References

1. Comerci JT, et al. Mature cystic teratoma: A clinicopathologic evaluation of 517 cases and review of the literature. *Obstet Gynecol.* 1994;84(1):22-8.
2. Taner ZM, et al. [Clinical and Therapeutic Approaches in Maturing Cystic Teratomas.] *T Klin J Gynecol Obst.* 1995;5(4):303-6.
3. Outwater EK, Siegelman ES, Hunt JL. Ovarian teratomas: tumor types and imaging characteristics. *Radiographics.* 2001;21(2):475-90.
4. Özcan R, et al. Ovary-sparing surgery for teratomas in children. *Pediatr Surg Int.* 2013 ;29(3):233-7. doi: 10.1007/s00383-012-3228-x.
5. Templeman CL, et al. Managing mature cystic teratomas of the ovary. *Obstet Gynecol Surv.* 2000;55(12):738-45.
6. Târcoveanu E, et al. Laparoscopic approach to ovarian dermoid cysts. *Chirurgia (Bucur).* 2012;107(4):461-8.
7. Koonings PP, et al. Relative frequency of primary ovarian neoplasms: a 10-year review. *Obstet Gynecol.* 1989;74(6):921-6.
8. Dolan MS, Boulanger SC, Salameh JR. Laparoscopic management of giant ovarian cyst. *JSLs.* 2006;10(2):254-6.
9. Eltabbakh GH, Charboneau AM, Eltabbakh NG. Laparoscopic surgery for large benign ovarian cysts. *Gynecol Oncol.* 2008;108(1):72-6.
10. Devoize L, et al. Giant mature ovarian cystic teratoma including more than 300 teeth. *Oral Surg Oral Med Pathol Oral Radiol Endod.* 2008;105(3):e76-9. doi: 10.1016/j.tripleo.2007.10.001.
11. Conway AZ, Hanna T. Dermoid cyst fistulating with the transverse colon. *Ann R Coll Surg Engl.* 2012;94(7):e230-1. doi: 10.1308/003588412X13373405385935.
12. Ayhan A, et al. Complications and bilaterality of mature ovarian teratomas (clinicopathological evaluation of 286 cases). *Aust N Z J Obstet Gynecol.* 1991;31(1):83-5.
13. Bal A, et al. Malignant transformation in mature cystic teratoma of the ovary: report of five cases and review of the literature. *Arch Gynecol Obstet.* 2007;275(3):179-82.
14. Avcı S, et al. Squamous cell carcinoma arising in a mature cystic teratoma. *Case Rep Obstet Gynecol.* 2012;2012:314535. doi: 10.1155/2012/314535.
15. Peterson WF. Malignant degeneration of benign cystic teratomas of the ovary; a collective review of the literature. *Obstet Gynecol Surv.* 1957;12(6):793-830.
16. Kido A, et al. Dermoid cysts of the ovary with malignant transformation: MR appearance. *AJR Am J Roentgenol.* 1999;172(2):445-9.
17. Takemori M, Nishimura R. MRI findings of an ovarian dermoid cyst with malignant transformation. *Magn Reson Med Sci.* 2003;2(2):105-8.
18. Park SB, et al. Preoperative diagnosis of mature cystic teratoma with malignant transformation: analysis of imaging findings and clinical and laboratory data. *Arch Gynecol Obstet.* 2007;275(1):25-31.
19. Yahata T, et al. Adenocarcinoma arising from respiratory ciliated epithelium in benign cystic teratoma of the ovary: a case report with analyzes of the CT, MRI, and pathological findings. *J Obstet Gynaecol Res.* 2008;34(3):408-12. doi: 10.1111/j.1447-0756.2008.00784.x.
20. Takai M, et al. Mucinous adenocarcinoma of the intestinal type arising from mature cystic teratoma of the ovary: a rare case report and review of the literature. *J Ovarian Res.* 2012 5;5(1):41. doi: 10.1186/1757-2215-5-41.

21. Kataoka T, Watanabe Y, Hoshiai H. Retrospective evaluation of tumor markers in ovarian mature cystic teratoma and ovarian endometrioma. *J Obstet Gynaecol Res.* 2012 ;38(8):1071-6. doi: 10.1111/j.1447-0756.2011.01833.x.
22. Var T, et al. Tumor markers panel and tumor size of ovarian dermoid tumors in reproductive age. *Bratisl Lek Listy.* 2012;113(2):95-8.
23. Ugur MG, et al. Do high levels of CA 19-9 in women with mature cystic teratomas of the ovary warrant further evaluation? *Eur J Gynaecol Oncol.* 2012;33(2):207-10.
24. Hackett A, et al. Squamous-cell carcinoma in mature cystic teratoma of the ovary: systematic review and analysis of published data. *Lancet Oncol.* 2008;9(12):1173-80. doi: 10.1016/S1470-2045(08)70306-1.
25. Goh SM, et al. Minimal access approach to the management of large ovarian cysts. *Surg Endosc.* 2007;21(1):80-3.
26. Murawski M, et al. Laparoscopic management of giant ovarian cysts in adolescents. *Wideochir Inne Tech Maloinwazyjne.* 2012;7(2):111-3. doi: 10.5114/wiitm.2010.22530.
27. Godinjak Z, Bilalović N, Idrizbegović E. Laparoscopic treatment of ovarian dermoid cysts is a safe procedure. *Bosn J Basic Med Sci.* 2011;11(4):245-7.